Current usage of monophasic latest generation implant devices (one-piece)

Dario Spitaleri[1], Maciej Michalak[2], Andrea Palermo[3], Andrzej Bożyk[4], Grigore Ion Lazarescu[5]

[1] Studio Odontoiatrico Associato Dr. I Spizzo E Spitaleri Clinica Medica Safe Spitaleri Via Lungolavia 1 – Palazzo Inserco Martignacco (Ud) Italia

[2] Military Institute of Medicine, Warsaw, Poland

Private practice in Lecce, senior clinical lecturer BBP University city of London, United Kingdom

[4] Department of Dental Prosthetics, Medical University of Lublin, Poland

[5] Corresponding Author at 'Titu Maiorescu' University, Faculty of Dentistry – Bucharest, Romania

European Journal of Medical Technologies
2016; 2(11): 7-14

www. medical-technologies.eu
Published online 19.07.2016

Corresponding address:
Studio Odontoiatrico Associato
Dr.I Spizzo E Spitaleri
Clinica Medica
Safe Spitaleri
Via Lungolavia 1 –
Palazzo Inserco
Martignacco (Ud) Italia
www.spitaleri.it

www.spizzospitaleri.it
tel.+390432657187

Abstract

The purpose of this article is to redefine, in a modern way and in light of current technology and industrial engineering, the clinical and biomechanical concepts of the monophasic implant to assess the rational use through a comparison with biphasic implant devices..Maintaining crestal bone has become in recent years a key criterion in assessing the success of an implant. The ideal case would be the homogeneous distribution of the loads along the entire contact bone/implant surface. The work presented here has set itself the objective of assessing the biomechanical behavior in the short and medium term of the IMMEDIATELOAD SA (Lugano-CH) dental implant – line POWER – then loaded by a denture of crown type. To increase the functional surface area of the POWER implant, the IMMEDIATELOAD SA Company has also acted on the depth of the

Key words:

Monophasic implants, Crestal bone loss, POWER Immediateload SA

coils. In the light of modern possibilities of computerized preoperative analysis, the author's intent is to evaluate and propose the monophasic implants as an alternative rational therapeutic choice in the prosthetic-implant rehabilitation with the help of modern knowledge and technology currently available of the design area, of surface treatment and of the performing precision. Case report.

Introduction

The medical devices for intraosseous implantology are developed with the currently known concepts and features since the 60s of last century. With the contribution of Dr. Tramonte and other authors the first case reports were written and the first publications appeared on the topic of the treatment of various kinds of edentulous patients with the use of screw type fixture implants made of titanium. The implant design and implementation of the fixtures are the result of clinical experience and technology available at the time.

The purpose of this short article is to redefine, in a modern way and in light of current technology and industrial engineering, the clinical and biomechanical concepts of the monophasic implant to assess the rational use through a comparison with biphasic implant devices.

The criteria for the success of implant therapy such as the stillness of the individual implants, the absence of the peri-implant radiolucency, the total absence of bone resorption, of pain, of inflammation and paresthesia may be currently considered the benchmarks for he rated short-term and long-term survival.

Numerous studies have shown a high success rate of dental implants (over 95% after 10 years), but the complications around the implant as peri-implantitis and crestal marginal bone loss at the implant neck are still under evaluation, study and research. **Maintaining crestal bone has become in recent years a key criterion in assessing the success of an implant.** The loss of marginal bone around an implant depends on several factors including the distribution of loads in relation to the quality and quantity of the bone surrounding the implant, which has got a primary importance. The latter factor has become a key issue in the long-term evaluation of an implant success. As a matter of fact, the bone has the ability to adapt its structure through the processes of resorption and deposition due to mechanical stimuli to which it is subjected during the chewing cycles.

The ideal case would be the homogeneous distribution of the loads along the entire contact bone/implant surface which is, however, in direct relation with the type of implant geometry and with the chemical-physical characteristics of the implant material.

It's now scientifically consolidated the fact that the biomechanical aspect of osseous-integrated dental implants is directly dependent on the geometry of the implant with particular reference to the fixture profile and the shape of the emerging part and the surface treatment of the implantable device.

Materials and methods

The work presented here has set itself the objective of assessing the biomechanical behavior in the short and medium term of the IMMEDIATELOAD SA (Lugano-CH) dental implant – line *POWER* – then loaded by a denture of crown type.

A peculiar characteristic of this device is the fact that the implant has been specifically designed and it has got, on its intraosseous area, the '*V' shape standard coils* which are used for the insertion and the stabilization of the implant in the bone, in association with '*square' shape coils* which are the key issue so as to make the load transfer to the surrounding biological tissue homogeneous and uniform.

To increase the functional surface area of the POWER implant, the IMMEDIATELOAD SA Company has also acted on the depth of the coils. The depth of the loop is the distance between the major diameter and the minor diameter of the loop. This coils depth varies along the implant body to provide greater functional surface in the regions of greatest stress (crestal area).

Case report

In light of the promising results obtained through the analysis of simulated biomechanics finite elements produced by bio - engineers at IMMEDIATELOAD SA, it is presented in this report the resolution of a case of single edentulous with an evidence-based indication for a bi-phasic implant associated with alveolar bone regeneration, using a monophasic device in order to evaluate the latest generation characteristics of the implant design, of the surface treatment and of the implant behavior in the process of bone rearrangement.

Description

Male patient, 56 years old, comes to my attention for the edentulous resolution of 4.6 lower first molar, on the right side, recently extracted for endo-periodontal reasons.

Within the anamnesis there were no local or general diseases or contraindications to an implant-prosthetic rehabilitation. On objective examination there comes out the lack of the tooth, signs of remodeling following the recent tooth extraction (after 45 days) with good preservation of soft tissue.

Radiographic examination is highlighting a localized radio-transparent area which is a sign of post-extractive bone gap. (Fig.1)

Materials and methods

The clinical and radiographic analysis of the case in question associated with the latest bibliographic support favors the resolution of this ***edentulia*** type associated with localized atrophy of edentulous alveolar area through a two-phase implant – prosthetic treatment with a submerged device and contextual tissue regeneration.

Comforted by the biomechanical analysis and *in vitro* tests, by the geometry of the implant design and by the latest generation osseous-causing implant surface, a minimally invasive solution was chosen for the resolution of this case through the use of a monophasic medical device – Power 4 * 11.5mm (*IMMEDIATELOAD SA* – Lugano CH) type.

It was planned, therefore, a unique flapless-type surgery, a one-piece implant insertion and immediate loading through a temporary dental crown.

After performing disinfection of the oral cavity (chlorhexidine 0.2% for 1 minute), local anesthesia was performed in the plexus, buccal and lingual area, in the ex 06.04 region (*Mepivacaine* 1:50: 000). (Fig 2)

Following the recommended operation surgery sequence of the manufacturer, milling osteotomy has been performed in the implant site using the *flapless* technique for a proper preservation of the periodontal tissues. The implant was manually entered using a dedicated screwdriver which was finalized with a ratchet programmed to 25N torque. (Fig 3)

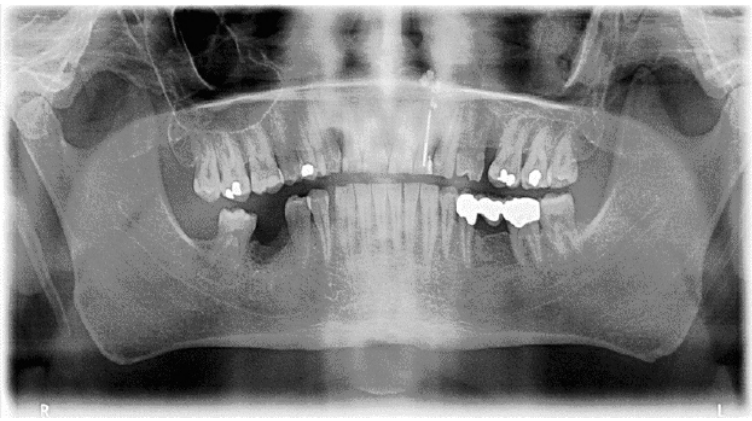

Fig. 1.
OPT pre-operative

Fig. 2.
Operative site

To promote quiescence of the implant and to limit potential overloads of the chewing and of the tongue thrust, the *POWER* implant was immobilized with splints by an intraoral welder (*DentWeld*) to the surrounding teeth elements which were not periodontally compromised.

To make such way to facilitate the osseous-genetic process, the implant was immediately loaded with temporary resin crown.

Within the three subsequent months, pending completion of the osseous-integration process, the implant was monthly monitored by an intraoral radiograph that showed a gradual bone consolidation on the implant surface. (Fig. 4-13)

At the end of the osseous-integrative process, the implant was finalized by a final alloy-composite crown and annually monitored. (Fig 14-17)

Conclusions

In the past, but also currently in some nowadays areas, the clinical use of the monophasic implants has been remarkable, especially in Italy, where the one-piece implant technique associated with intraoral welding had its birth and its most widespread, despite the unequal distribution of studies and bibliographic analysis comparing to the biphasic devices which had a greater use.

In the light of modern possibilities of computerized preoperative analysis, the author's intent is to evaluate and propose the monophasic implants as an alternative rational therapeutic choice in the prosthetic-implant rehabilitation with the help of modern knowledge and technology currently available of the

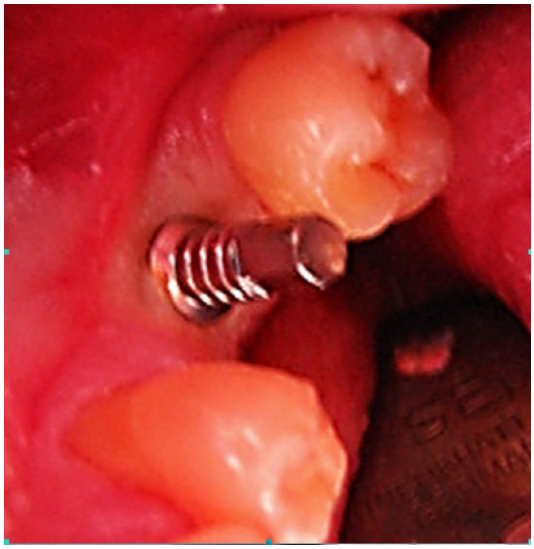

Fig. 3.
Power Implant inserted – flapless technique

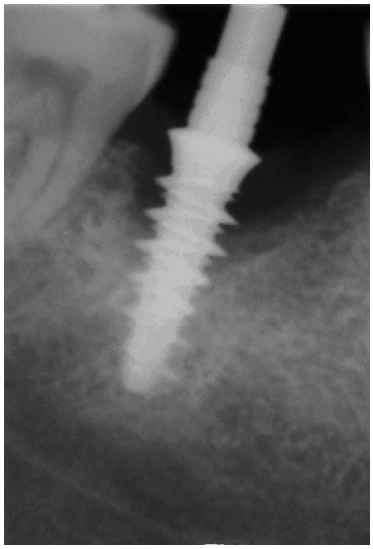

Fig. 4.
Rx intra-operative

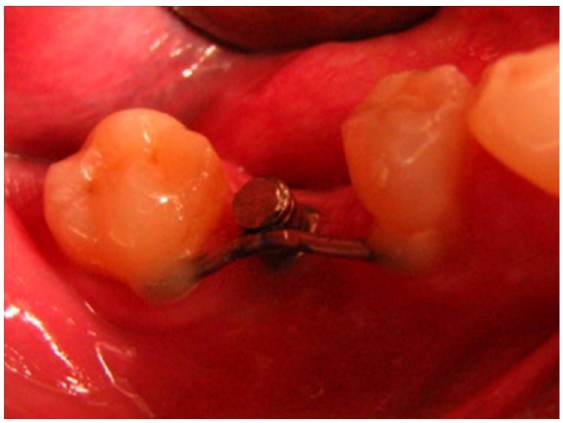

Fig. 5.
Splinting by means of electro-welding

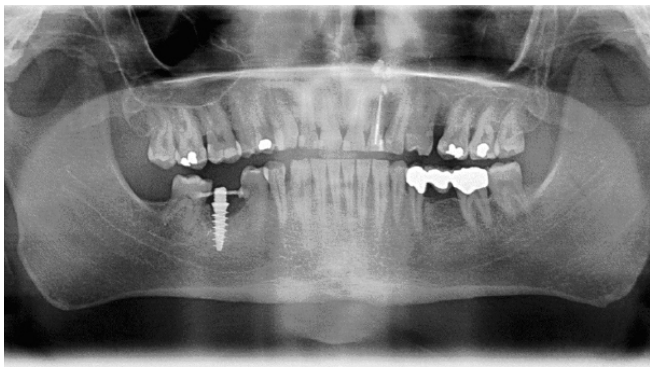

Fig. 6.
OPT post-operative

Fig. 7.
Provisional immediate

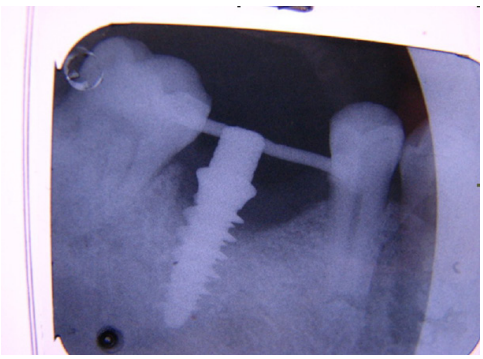

Fig. 8.
Rx control after 1 month

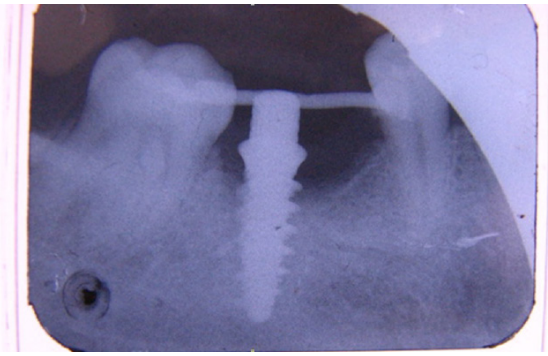

Fig. 9.
RX control after 2 months, after surgery

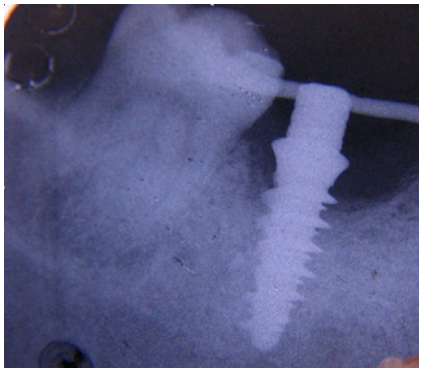

Fig. 10.
Rx control after 3 months

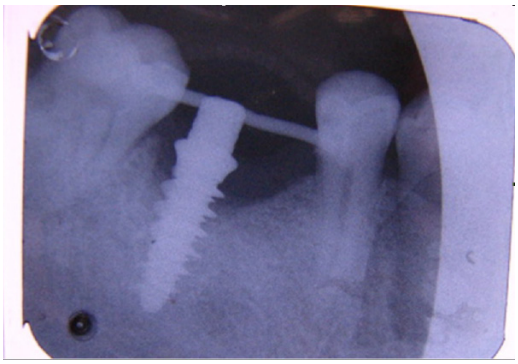

Fig. 11.
Rx control after 4 months

Fig. 12.
Clinic view after 4 months

Fig. 13.
Final crown

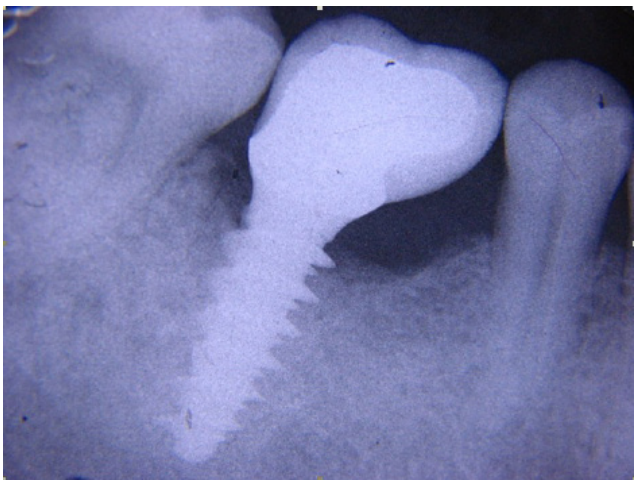

Fig. 14.
Rx control after 5 months

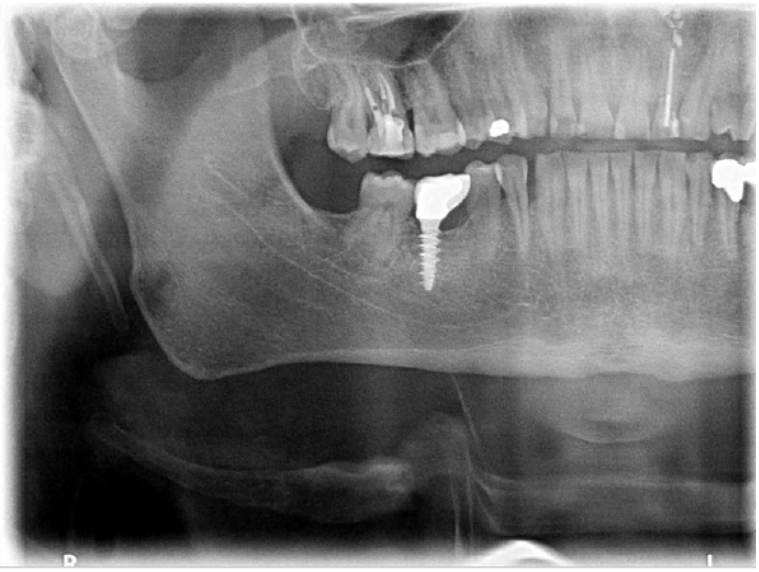

Fig. 15.
OPT control after 3 years

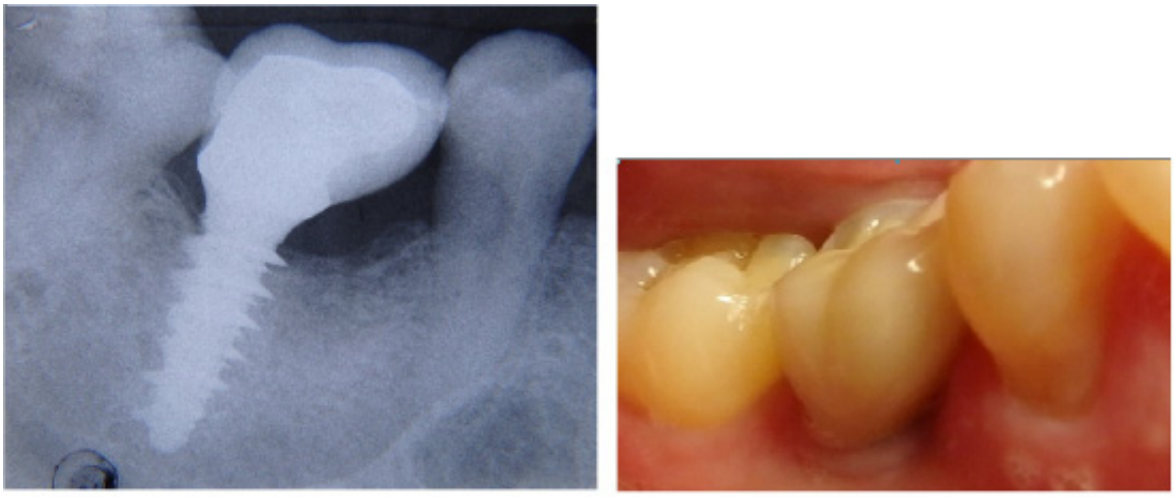

Fig. 16–17.
control RX and clinical after 4 years

design area, of surface treatment and of the performing precision.

In the executed clinical case, a latest generation monophasic implant was chosen having an osseous-causing surface where the surgical rational supported by the recent bibliography indicates, as a gold standard, the use of the biphasic implant associated with tissue regeneration.

The minimally invasive surgical technique involved the '*flapless*' insertion of the device to better respect periodontal tissues and the regenerative potential of the residual socket. During the osseous-integration process a soft tissues consolidation was highlighted as well as a progressive osseous-densification of the bone tissue on the coils and on the implant surface that allowed the total osseous-integration of the device, where no kind of pathological survey could show. The implant abutment was immediately finished after the insertion so as to prevent possible micro-traumas in the consolidation phase.

Not reaching 30N torque of primary stability, a further stabilization process through intraoral welding was chosen, by splinting to adjacent elements which did not show any type of periodontal impairment. The implant was immediately loaded with resin temporary crown out of occlusion to promote the mastication osseous-inductive stimuli.

After four months, comforted by radiographic examination and by optimal secondary stability, the implant has been finalized with a final alloy – composite crown, every six months clinically monitored and annually radiographically monitored.

The clinical case individually taken into account requires of course further discussion, a proper evaluation and long-term monitoring, but it highlights the possible resolution of the partial and total edentulous issues through also a rational use of the latest generation monophasic implants properly selected and used.

Experience and personal considerations

I have been using the implant lines of IMMEDIATE-LOAD SA and I am honored to serve on the Opinion Leader Committee. In recent years I have used more than 800 POWER monophasic implants with considerable satisfaction with the surgery quality and the results of the implant survival that in my personal case histories goes up to 95,8% success and I have been using these implants even in those cases in which they could not find primary indication such as vertical and horizontal atrophy or mini and large maxillary sinus lift with lateral and crestal approach.

Bibliografia

1. UNI EN 1642. Dispositivi medici per l'odontoiatria. Impianti dentali. Milano: Ente Nazionale Italiano di Unificazione; 1997.
2. ISO TR 11175. Dental implants. Guidelines for development dental implants. Geneva: International Organization for Standardization; 1993.
3. Brunski JB. Biomaterials and biomechanics in dental implant design. Int J Oral Maxillofac Implants 1988; 3(2): 85-97.
4. Lekholm U, Zarb GA. Tissue integrated prostheses: osseointegration in clinical dentistry. Chicago: Branemark, Zarb & Albrektsson Eds.; 1985.
5. Albrektsson T, Bränemark PI, Hansson HA, Lindstrom J. Osseointegrated titanium implants. Requirements for ensuring a long lasting, direct bone anchorage in man. Acta Orthop Scand 1981; 52(2): 155-70.
6. Adell R, Lekholm U, Rockler B, Bränemark PI. A 15-year study of osseointegrated implants in the treatment of the edentulous jaw. Int J Oral Surg 1981; 10(6): 387-416.
7. Bränemark PI, Adell R, Breine U, Hansson BO, Lindstrom J, Ohlsson A. Intra-osseous anchorage of dental prostheses I. Experimental studies. Scand J Plast Reconstr Surg 1969; 3: 81-100.
8. Asikainen P, Klemetti E, Vuillemin T, Sutter F, Rainio V, Kotilainen R. Titanium implants and lateral forces. An experimental study with sheep. Clin Oral Implants Res 1997; 8(6): 465-468.
9. Keltjens HMAM, Creugers TJ, Creugers NHJ. Three different filling materials in overdenture abutments; a 30-months evaluation. J Dent Res 1997; 76(5):1103.
10. Weinlaender M. Bone growth around dental implants. Dent Clin North Am 1991; 35: 585-601.

11. M. Marincola, L. Paracchini, V. Morgan, J. Schulte. Impianti corti: principi biomeccanici e predicibilità a lungo termine. Quintessenza Internazionale 2008, Settembre-Ottobre 2008, 45-53, 24, 5bis.
12. M. Danza, I. Zollino, L. Paracchini, G. Riccardo, S. Fanali, F. Carinci. 3D finite element analysis to detect stress distribution: Spiral family implants. J. Maxillofac. Oral Surg 8(4): 334-339.
13. M. Danza, I. Zollino, L. Paracchini, I. Vozza, R. Guidi, F. Carinci. 3D finite element analysis comparing standard and reverse conical neck implants: Bone platform switching. EDI Journal. 2(2010):334-339.
14. M. Danza, A. Quaranta, F. Carinci, L. Paracchini, G. Pompa, I. Vozza. Biomechanical evaluation of dental implants in D1 and D4 bone by Finite Element Analysis. Minerva Stomatol. 2010 Jun;59(6):305-13. English, Italian.
15. M. Danza, L. Paracchini, F. Carinci. Analisi agli elementi finiti per la definizione della distribuzione degli stress meccanici negli impianti. Dental Cadmos 2012; 80(10): 598-602.